

CORRESPONDENCE

Importation and Human-to-Human Transmission of a Novel Coronavirus in Vietnam

TO THE EDITOR: The emergence and spread of a novel coronavirus (2019-nCoV) from Wuhan, China, has become a global health concern.¹ Since the detection of the coronavirus in late December 2019, several countries have reported sporadic imported cases among travelers returning from

China.² We report one family cluster of 2019-nCoV originating from a Chinese man.

On January 22, 2020, a 65-year-old man with a history of hypertension, type 2 diabetes, coronary heart disease for which a stent had been implanted, and lung cancer was admitted to the emer-

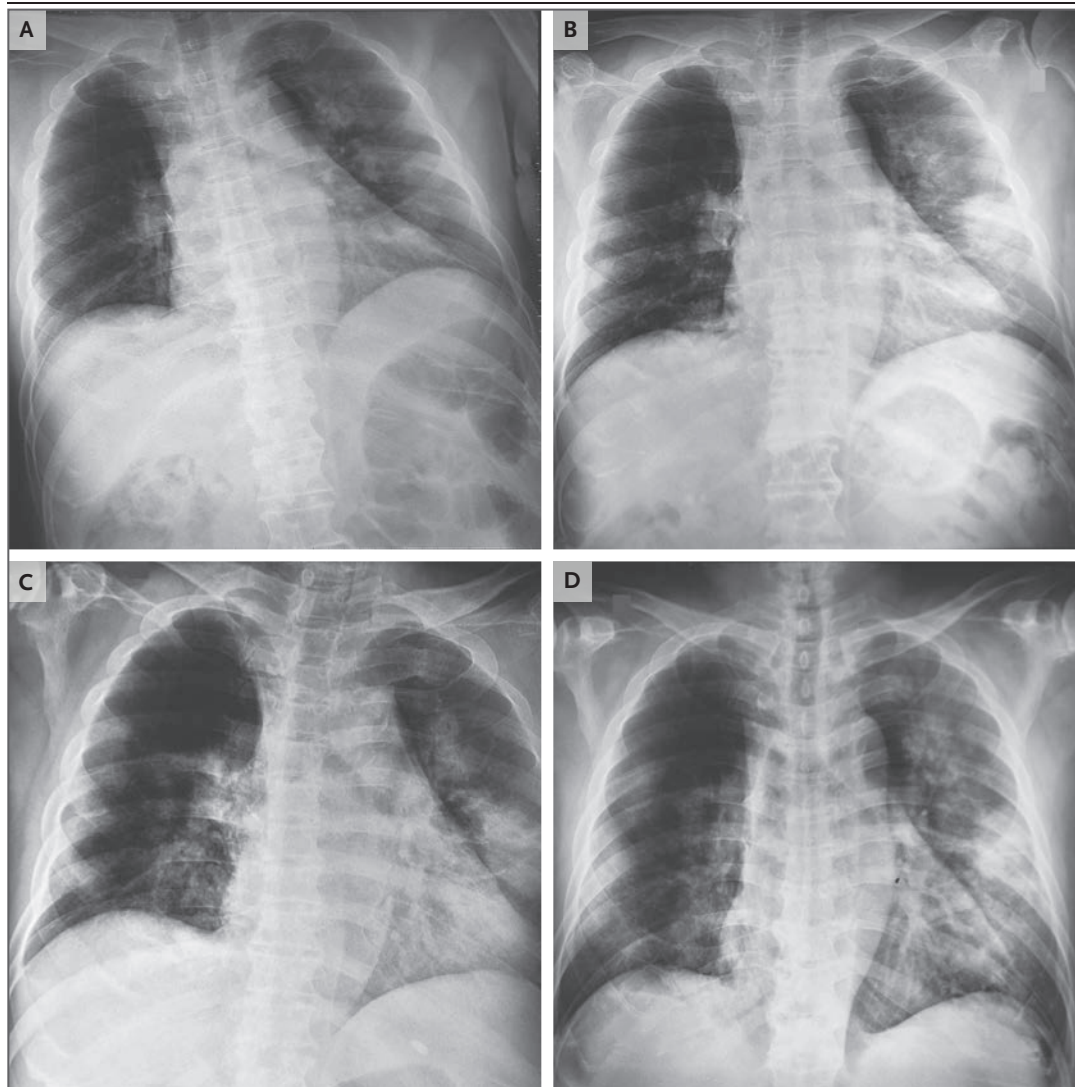


Figure 1. Radiographs of the Father's Chest.

Shown are chest radiographs obtained at admission (Panel A) and on day 3 (Panel B), day 5 (Panel C), and day 6 (Panel D) after admission.

gency department of Cho Ray Hospital, the referral hospital in Ho Chi Minh City, for low-grade fever and fatigue. He had become ill with fever on January 17, a total of 4 days after he and his wife had flown to Hanoi from the Wuchang district in Wuhan, where outbreaks of 2019-nCoV were occurring. He reported that he had not been exposed to a “wet market”(a market where dead and live animals are sold) in Wuhan.

Throat swabs obtained from the patient tested positive for 2019-nCoV on real-time reverse-transcription–polymerase-chain-reaction (RT-PCR) assays.³ On admission to the hospital, the man was isolated and treated empirically with antiviral agents, broad-spectrum antibiotics, and supportive therapies. Chest radiographs obtained on admission showed an infiltrate in the upper lobe of the left lung (Fig. 1A). On January 25, he received supplemental oxygen through a nasal cannula at a rate of 5 liters per minute because of increasing dyspnea with hypoxemia. The partial pressure of oxygen was 57.2 mm Hg while he was breathing ambient air, and a progressive infiltrate and consolidation were observed on chest radiographs (Fig. 1B through 1D). His fever disappeared on January 25, and his clinical condition has improved since January 26. His wife had no symptoms of illness while they were traveling. She was healthy as of January 28.

The couple’s healthy 27-year-old son had lived in Long An, a province 40 km southwest of Ho Chi Minh City, since October 2019. He had not traveled to a region where 2019-nCoV was spreading, and he had not had any known contact with any person returning from such a region. On January 17, he met his father in Nha Trang in central Vietnam and shared a bedroom with his parents for 3 days in a hotel room that had an air conditioner. On January 20, a dry cough and fever developed in the son. He also reported having had vomiting and loose stools one time before the admission. This suggests that the incubation period for 2019-nCoV may have been 3 days or less in this case. When the son presented at Cho Ray Hospital with his father on January 22, his illness, characterized by a fever (39°C), was recognized and he was immediately isolated. Chest radiographs and other laboratory examinations in this patient showed no abnormalities except for an increased level of C-reactive protein (13.9 mg per liter). Real-time RT-PCR assays for influenza A and B viruses and nonstructural protein 1 antigen rapid tests for dengue viruses

were negative in both the father and son. A throat swab in the son was positive for 2019-nCoV. His father was thought to be the source of infection. However, sequencing of strains from the two patients to ascertain the transmission of 2019-nCoV from the father to son has not been performed. The son’s condition was stable after January 23.

This family had traveled to four cities across Vietnam using various forms of transportation, including planes, trains, and taxis. A total of 28 close contacts have been identified, and symptoms of an upper respiratory infection have not developed in any of them. This family cluster of 2019-nCoV infection that occurred outside China⁴ arouses concern regarding human-to-human transmission.

Lan T. Phan, Ph.D.
Thuong V. Nguyen, M.D., Ph.D.
Quang C. Luong, M.D.
Thinh V. Nguyen, M.D.
Hieu T. Nguyen, B.Sc.
Pasteur Institute Ho Chi Minh City
Ho Chi Minh City, Vietnam
nguyenthuong@yahoo.com

Hung Q. Le, M.D., Ph.D.
Thuc T. Nguyen, M.D.
Cho Ray Hospital
Ho Chi Minh City, Vietnam

Thang M. Cao, Pharm.D.
Quang D. Pham, M.D., Ph.D.
Pasteur Institut Ho Chi Minh City
Ho Chi Minh City, Vietnam

Drs. Phan, Thuong V. Nguyen, and Pham contributed equally to this letter.

Disclosure forms provided by the authors are available with the full text of this letter at NEJM.org.

This letter was published on January 28, 2020, at NEJM.org.

1. Zhu N, Zhang D, Wang W, et al. A novel coronavirus from patients with pneumonia in China, 2019. *N Engl J Med*. DOI: 10.1056/NEJMoa2001017.
2. Novel coronavirus (2019-nCoV): Situation report – 5, 25 January 2020. Geneva: World Health Organization, 2020 (<https://www.who.int/docs/default-source/coronaviruse/situation-reports/20200125-sitrep-5-2019-ncov.pdf>).
3. Corman V, Bleicker T, Brünink S, et al. Diagnostic detection of Wuhan coronavirus 2019 by real-time RT-PCR. Geneva: World Health Organization, January 13, 2020 (<https://www.who.int/docs/default-source/coronaviruse/wuhan-virus-assay-v1991527e5122341d99287a1b17c111902.pdf>).
4. Huang C, Wang Y, Li X, et al. Clinical features of patients infected with 2019 novel coronavirus in Wuhan, China. *Lancet*. January 24, 2020 ([https://www.thelancet.com/journals/lancet/article/PIIS0140-6736\(20\)30183-5/fulltext](https://www.thelancet.com/journals/lancet/article/PIIS0140-6736(20)30183-5/fulltext)).

DOI: 10.1056/NEJMc2001272

Correspondence Copyright © 2020 Massachusetts Medical Society.